

Variation in Median Nerve Formation-A Case Report

Dr Shobha Verma^{^*} and Dr Manisha Nakhate[#]

[^]Assistant Professor Anatomy, [#]Professor and Hod Anatomy, D Y Patil, School of Medicine Navi Mumbai, India

Received 20 Sept 2020, Accepted 05 Nov 2020, Available online 10 Nov 2020, Vol.8 (Nov/Dec 2020 issue)

Abstract

Introduction- Normally median nerve is formed lateral to third part of axillary artery by the union of a lateral root from lateral cord and a medial root from the medial cord. Formation is Y- shaped. medial root crosses in front of III part of Axillary artery A number of variations in the formation of median nerve, its relationship to the axillary artery and communication with musculocutaneous nerve have been reported by earlier workers.in the present study during routine anatomical dissection we encountered interesting case of variations in the formation of median nerve in the axilla

Case report -In an aged male cadaver on the right-side median nerve is formed by three roots,1 lateral root and 2 medial roots

Clinical importance -Knowledge of the various types of median nerve formation and the variable relationship of the roots of median nerve to the axillary artery and association of vascular anomalies is very important during surgeries in the axillary region. Injury to such a variant nerve may lead to a galaxy of manifestations Clinical implications of such variations have to be kept in mind during anesthetic procedures of brachial plexus, shoulder arthroscopy, traumatic injuries involving axillary region.

Keywords: Median nerve, lateral root medial root clinical implications

Introduction

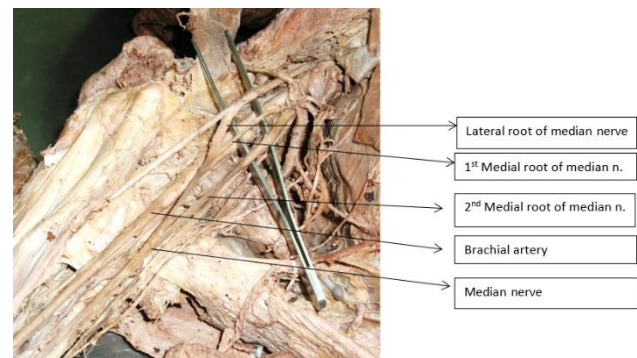
Normally median nerve is formed lateral to third part of axillary artery by the union of a lateral root from lateral cord and a medial root from the medial cord. Formation is Y- shaped.

Medial root crosses in front of III part of Axillary artery A number of variations in the formation of median nerve, its relationship to the axillary artery and communication with musculocutaneous nerve have been reported by earlier workers. In the present study during routine anatomical dissection we encountered three interesting cases of variations in the formation of median nerve in the axilla. Some of these variations are accompanied by vascular anomalies also as reported in the earlier literature

Case Report

In an aged male cadaver on the right-side median nerve is formed by three roots, 1 lateral root and 2 medial roots. Note the smaller medial root joins more proximally & the larger one distally.

Median nerve lies medial to axillary artery Note the lateral root crossing in front of III part of axillary artery to join the medial root medial to artery.



Median nerve formation by two medial cords

Discussion

We find very less reports of presence of 2 medial roots. Abhaya *et al* 2003, Sathyanarayana *et al* 2010 (2), Uzun and Seelig 2001(4) reported the formation of median nerve by 4 roots, 3 from lateral & 1 from medial cord.(1)

Bhanu *et al*, 2010 described a case of absence of medial root and the formation of median nerve by a single root from lateral cord.

*Corresponding author's ORCID ID: 0000-0002-8137-9141
DOI: <https://doi.org/10.14741/ijmcr/v.8.6.1>

Pandey & Shukla, 2006 reported the formation of Median nerve by the contribution from all the three cords of brachial plexus (3).

Reference

- [1]. Abhaya A, Khanna J and Prakash R; Variation of lateral cord of brachial plexus piercing coracobrachialis muscle, Journal of Anatomical Society of India (2003) Volume 52 (2), page 168-170
- [2]. Satyanarayana N, Vishwakarma N, Kumar GP, Guwa R, Dutta AK and Sunitha P; Variation in relation of cord of brachial plexus and their branches with axillary and brachial artery- a Case report, Nepal Medical College Journal (2009), Volume 11 (1) page 69-72
- [3]. Pandey and Shukla V; Anatomical variation of cord of brachial plexus and median nerve, Clinical Anatomy (2007) volume 20, page 150-156
- [4]. Uzun A, Seeling L; A variation in the formation of median nerve communicating branch between musculocutaneous nerve and median nerve, Folia Morphologica, 2001 volume 60 (2) page 99-101