

## Surgical and Clinical Review of Acute Appendicitis

Dr. Abbas Abdul Mahdi Kadim

AL- Sader Educational Hospital, AL Najaf- Governorate /Iraq

Accepted 01 April 2016, Available online 06 April 2016, Vol.4 (March/April 2016 issue)

### Abstract

Appendix or vermiform appendix; also called cecal or caecal appendix; also vermiform). All researchers defined it as a blind-ended tube connected to the cecum. The cecum is a pouch like structure of the colon, localized at the junction point of the large and small intestines. Appendicitis is caused by a blockage of the hollow portion of the appendix, most commonly by a calcified "stone" made of feces. However, inflamed lymphoid tissue from a microbial infection, parasites, gallstone as well as tumors may also lead to the appendix blockage. Appendicitis diagnosis is largely based on signs and symptoms. When the diagnosis cannot be made based on the person's history and physical exam; specialists must go to laboratory tests, radiographic imaging and close observations can often be helpful. The two most common imaging tests used are ultrasound and computed tomography (CT scan). The first treatment option for acute appendicitis is surgical removal of the appendix, through open incision in the abdomen (laparotomy) or by a few smaller incisions with cameras (laparoscopy). To decrease the risk of side effects during surgical removal some surgeons used alternative line treatment which is antibiotics to avoid rupture appendicitis during surgical operation. In 2013 acute appendicitis resulted in 72,000 deaths globally.

**Keywords:** Acute Appendicitis, Surgical, Clinical, Iraq

### 1. Epidemiology

Appendicitis is a common case between the ages of 5 to 40 year. The average age of infection is 28 (figure. 1), it tends to affect male more than female. Appendicitis accrue in lower income peoples, persons living in rural areas, and for unknown reasons. Several Studies in the USA demonstrated that nearly 293,000 hospitalizations involving appendicitis in 2010. Whereas about 10% of the individuals will develop acute appendicitis in UK (1). In 2013 appendicitis resulted in 72,000 deaths globally down from 88,000 in 1990 (2,3,4).

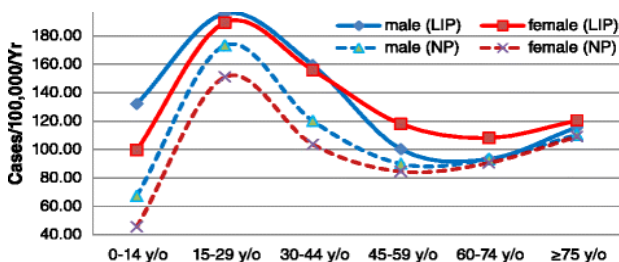


Figure 1. Incidence of Appendicitis by age & Gender

### 1.2. Histology

Appendix considered as a small tubular extension of the right side of the colon. The length of appendix in adult

human averaged 9 cm and generally ranged from 2 to 20 cm. While it's width ranged between 7 to 8 mm (Figure. 2). In 2011 the longest appendix measured 26 cm removed from a patient in Zagreb in Croatia. Appendix is typically sited in the right lower quadrant of the abdomen, near the right hip. Its location in the abdomen matches to a site on the surface known as McBurney's (5,6).

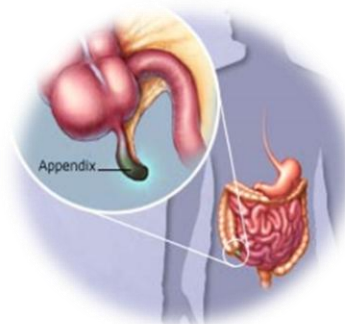


Figure 2: Site of Human Appendix

### 1.3 Variation

Some of identical twins-known as mirror image twins (such mirror image twins result when a fertilized egg splits later in the embryonic stage than normal timing,

around day 9-12. This kind of twinning could exhibit characteristics with reversed asymmetry; can have a mirror-imaged anatomy *situs inversus*; is a genetic disorder that makes the organs in the abdomen and chest to be positioned in a mirror image from their normal positions. Such as the left atrium of the heart and the left lung are positioned on the body's right side, and vice-versa. In case of abdominal cavity, the appendix is sited predominantly on the left side instead of the right, and the stomach is on the right side instead of the left. The location of the tip of the appendix can vary from being retrocecal (behind the cecum) (74%) to being in the pelvis to being extra peritoneal (7,8).

## 1.4 Function

### 1.4.1 Maintaining gut flora

For many years all if not most researchers were thought that no purpose of appendix. But now, researchers discovered the real function of this organ. Many studies revealed that the appendix acts as a safe house for good bacteria. Our bodies used this to essentially "reboot" the digestive system when one suffers from a bout of dysentery or cholera (9,10,11).

In 2007 some researchers at Duke University showed that the appendix serves as a haven or protection for useful bacteria when illness flushes those bacteria from the rest of the intestines (10,12). Such fact is depend on a new understanding of how the immune cell system supports the growth of beneficial intestinal bacteria (13,14). In relationship with many well-known features of the appendix, including its architecture, its sited just below the normal one-way flow of food and germs in the large intestine, and its association with copious amounts of immune tissue. Study performed at Winthrop University-Hospital demonstrated that persons without an appendix were four times more likely to have a recurrence of colitis. So the acceptable conclusion that the appendix may act as a "safe house" for commensal ("good") bacteria. This reservoir of gut flora could then serve to repopulate the digestive system following of some infection like dysentery or cholera (15).

### 1.4.2 Vestigiality

Most of researchers defined the vestigiality that those traits (such as organs or behaviors) occurring in humans that have lost all or most of their original function through evolution. Human appendix had previously been proposed to be a vestigial organ. Other examples of human vestigiality are wisdom teeth, tailbone, and inside corner of the eye (16,17).

The appendix has been designed to be the shrunken remainder of the cecum that was found in a remote ancestor of humans. In 2013 several studies revealed that inverse relationship between cecum size and appendix size it was found (16). Cecum, which occur in the

digestive tracts of many herbivores (e.g. Ox, Horse), house mutualistic bacteria that help animals to digest the cellulose molecules found in grasses (17,18).

An acceptable scenario for the decline progression from a fully functional cecum to the current human appendix was put forth by (19). He explored that the appendix was used for digesting leaves as primates (primates included the familiar of the placental mammals, include us, primates also include familiar animals, such as the chimpanzees, gorillas, and monkeys, as well as lorises, galagos, pottos, sifakas, indris, aye-ayes, and tarsiers (18).

So that a vestigial organ of ancient humans that has degraded to nearly nothing over the course of evolution. The very long cecum of some herbivorous animals, such as found in the hours, appears to support this theory. Human ancestors may have also relied upon this system when they lived on a diet rich in foliage. As people began to eat more easily digested foods, they may have become less reliant on cellulose-rich plants for energy. As the cecum became less necessary for digestion, mutations that were previously deleterious (and would have hindered evolutionary progress) were no longer important, so the mutations have survived. It's suggested that these alleles became more frequent and the cecum continued to shrink (19).

### 1.4.3 Clinical Significance

The most common infection of human appendix is called appendicitis and carcinoid tumors (appendiceal carcinoid) (Wrongdiagnosis.com 2010a). percentage of appendix cancer about 1 in 200 of all gastrointestinal tumors. In rare cases, adenomas are also present. (20).

## 2. Appendicitis

Earlier studies defined the appendicitis that is an inflammation of the appendix organ. It may be chronic or acute. Harrison's principles of internal medicine states showed that appendicitis is the most common medical emergency in the American United States. More than 250,000 appendectomies are performed annually. Usually appendicitis occurs most often between the ages of 10 and 30. It is more common in men than in women. Untreated appendicitis may result in death. Typical symptoms of appendicitis commonly begin with right iliac fossa abdominal pain, vomiting, nausea, and finished with appetite (21). Generally, one third to a half of patients do not have these typical signs and symptoms (21). Severe complications of a ruptured appendix include wide spread, painful inflammation of the inner lining of the abdominal wall and sepsis (22).

Appendicitis is caused by a blockage of the hollow part of the appendix (23). most commonly by a calcification of feces. Inflamed lymphoid tissue from a viral infection, parasites, gallstone or tumors may also cause the blockage of appendix (24). Such blockage leads to

increased pressures within the appendix, decreased blood flow to the tissues of the appendix, and bacterial growth inside the appendix causing inflammation) (25, 26). The combination of inflammation, reduced blood flow to the appendix and distention of the appendix causes tissue injury and tissue death) (27). If this process is left untreated, the appendix may burst, releasing bacteria into the abdominal cavity, leading to severe abdominal pain and increased complications (25, 27).

## 2.1 Signs and symptoms

Firstly appendicitis start with the pain, then nausea and vomiting, and fever last has been described as the classic presentation of acute appendicitis infection. Du to the innervation of the appendix enters the spinal cord at the same level of umbilicus (belly button), the pain begins at stomach-high. When the appendix becomes more swollen and inflamed, it begins to irritate the adjoining abdominal wall. This situation leads to the sited of the pain to the right lower quadrant. This typical migration of pain may not be seen in baby under three years. This pain can be elicited through various signs and can be severe. Signs include localized findings in the right iliac fossa. The abdominal wall becomes very sensitive to gentle pressure (palpation). Also, there is severe pain on sudden release of deep pressure in the lower abdomen . If the appendix is retrocecal (localized behind the cecum), even deep pressure in the right lower quadrant may fail to elicit tenderness (silent appendix). This is because the cecum, distended with gas, protects the inflamed appendix from pressure. Similarly, if the appendix lies entirely within the pelvis, there is usually complete absence of abdominal rigidity. In such cases, a digital rectal examination elicits tenderness in the rectovesical pouch. Coughing causes point tenderness in this area (McBurney's point) (25, 26, 27).

## 2.2 Causes

According to experimental evidence, acute appendicitis seems to be the final result of a primary obstruction of the appendiceal lumen (23). When this obstruction occurs, the appendix becomes filled with mucus and swells then production of intra-luminal mucus leads to increased pressures in the lumen and the walls of the appendix. Increasing of pressure lead to thrombosis and occlusion of the small blood vessels, and stasis of lymphatic flow. At this level of infection spontaneous recovery rarely occurs. If the obstruction of small blood vessels progresses, the appendix becomes ischemic and then necrotic. When the bacteria start to leak out through the dying walls, pus cell within and around the appendix will be seen .The end result of this situation is appendix rupture (a 'burst appendix') causing peritonitis, which may lead to sepsis and eventually death (25, 27).

The causative agents of appendicitis include bezoars, foreign bodies, trauma, intestinal worms, lymphadenitis,

and, most commonly, calcified fecal deposits that are known as appendicoliths or fecaliths (27). The occurrence of obstructing fecaliths has attracted attention since their presence in persons with appendicitis is higher in developed than in developing countries (28). In addition an appendiceal fecalith is commonly associated with complicated appendicitis (29). Also, fecal stasis and arrest may play a role, as demonstrated by persons with acute appendicitis having fewer bowel movements per week compared with healthy controls (30, 31). The occurrence of a fecalith in the appendix was thought to be attributed to a right-sided fecal retention reservoir in the colon and a prolonged transit time. However a prolonged transit time was not observed in subsequent studies (32). From epidemiological data, it has been stated that diverticular disease and adenomatous polyps were unknown and colon cancer exceedingly rare in communities exempt from appendicitis) (33, 34). Also, acute appendicitis has been shown to occur antecedent to cancer in the colon and rectum (35). Several studies offer evidence that a low fiber intake is involved in the pathogenesis of appendicitis (34, 36, 37). This low intake of dietary fiber is in accordance with the occurrence of a right-sided fecal reservoir and the fact that dietary fiber reduces transit time (38).

## 2.3 Diagnosis

Generally appendicitis diagnosis is based on a medical history (symptoms) and physical examination which can be supported by an increase of neutrophilic white blood cells; Neutrophils are the primary white blood cells that respond to a bacterial infection. Usually the symptoms appear into two categories, typical and atypical. Typical appendicitis symptoms includes several hours of generalized abdominal pain which begins in the region of the umbilicus associated with anorexia, nausea, and vomiting. The pain then "localizes" into the right lower quadrant where the tenderness increases in intensity. The combination of pain, anorexia, leukocytosis, and fever are classic. Atypical histories lack this typical progression and may include pain in the right lower quadrant as an initial symptom. Irritation of the peritoneum can result in increased pain on movement, or jolting, for example going over speed bumps (39). Atypical histories often require imaging with ultrasound and/or CT (39).

Concerning clinical diagnosis included many ways ; firstly; Aure-Rozanova sign which is a medical sign that is typically seen in retrocecal appendix. It is characterized by Increased pain on palpation with finger in right Petit triangle (can be a positive Shchetkin-Bloomberg's) Bartomier-Michelson's sign: Increased pain on palpation at the right iliac region as the person being examined lies on his/her left side compared to when he/she lies on his/her back. Secondly; Dunphy's sign is Increased the pain at right lower quadrant with coughing.Thirdly; Kocher's (Kosher's) sign start from the pain in the umbilical region with a subsequent shift to the right iliac region (40).

Fourthly; Massouh sign characterized by increased abdominal pain with coughing. It may be an indicator of appendicitis. A positive Massouh sign is a grimace of the person being examined upon a right sided (and not left) sweep (40).

Fifthly; Obturator sign a sign of appendicitis or other peritoneal inflammation. The internal rotation of the right leg with the leg flexed to 90 degrees at the hip and knee and a resultant tightening of the internal obturator muscle may cause abdominal discomfort indicative of, for example, appendicitis (41).

Sixthly; Psoas sign is positive when there is an abdominal pain as the patient moves his leg against resistance. The abdominal pain is associated with reflexive or direct irritation of the psoas muscle. Positive psoas sign usually indicates localized abscess or appendicitis. Psoas sign may be elicited on the right or left sides. Psoas sign is elicited after performing a complete abdominal examination in a patient who complain of abdominal or lower back pain and inflammation of the psoas muscles themselves. Straightening out the leg causes pain because it stretches these muscles, while flexing the hip activates the iliopsoas and therefore also causes pain.

Eighth; Rovsing's sign: named after the Danish surgeon Niels Thorkild Rovsing (1862 -1927), is a sign of appendicitis. If palpation of the left lower quadrant of a person's abdomen increases the pain felt in the right lower quadrant, the patient is said to have a positive Rovsing's sign and may have appendicitis.

Ninthly; Sitkovskiy (Rosenstein)'s is a sign of acute appendicitis. It is observed, when tenderness in the right lower quadrant increases when the patient moves from the supine position to a recumbent posture on the left side (40,42,43).

## 2.4 Blood & Urine tests

Usually there is no laboratory specific test for diagnosis of appendicitis, a complete blood picture (CBP) is done to check for signs of infection. Although 70-90 % of people with appendicitis may have an elevated white blood cell (WBC) count, although other abdominal and pelvic conditions that can cause the WBC count to be elevated (44,45).

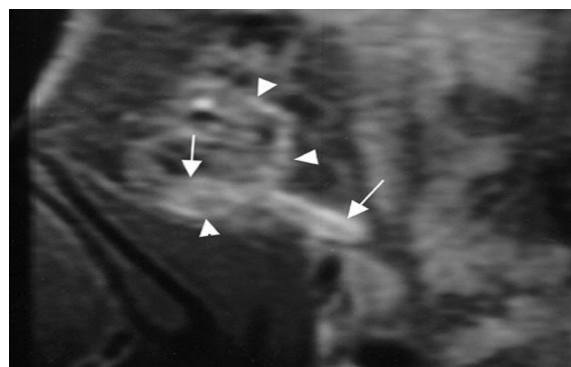
## 2.5 Imaging

Imaging in cases of children infection is important for detection of which children with abdominal pain should receive immediate surgical consultation and which should receive diagnostic imaging (34). Because of the side effects of exposing children to radiation, ultrasound be a favorite with a computed tomography (CT) scan being a legitimate follow-up if the ultrasound is inconclusive (35,46,47). CT scan is more accurate than ultrasound for diagnosis of acute appendicitis in adults and adolescents. CT scan has a sensitivity of 94%, specificity of 95%.

Ultrasonography had an overall sensitivity of 85%, a specificity of 82%. (48).

## 2.6 Ultrasound

Doppler sonography and Ultrasonography provide useful means to determination of appendicitis, especially in children. Ultrasound also can show the free fluid collection in the right iliac fossa, along with a visible appendix without blood flow when using color Doppler. In some cases (approximately 15%), ultrasonography of the iliac fossa does not reveal any abnormalities despite the presence of appendicitis. This false negative result finding is especially true of early appendicitis before the appendix has become significantly distended. In addition for that; false negative findings are more common in adults patients where larger amounts of fat and bowel gas make visualizing the appendix technically difficult. Despite these limitations, sonographic imaging with experienced hands can distinguish between the appendicitis and other diseases with similar symptoms. Some of these diseases include lymph nodes inflammation near the appendix or pain originating from other pelvic organs such as the ovaries or fallopian tubes. Other advanced radiologic examinations, acute appendicitis such as magnetic resonance imaging (MRI), scintigraphy, and color Doppler US, have been used in the diagnosis of acute appendicitis (Figure.3 ) with a diagnostic accuracy of approximately 91-95% (49, 50).

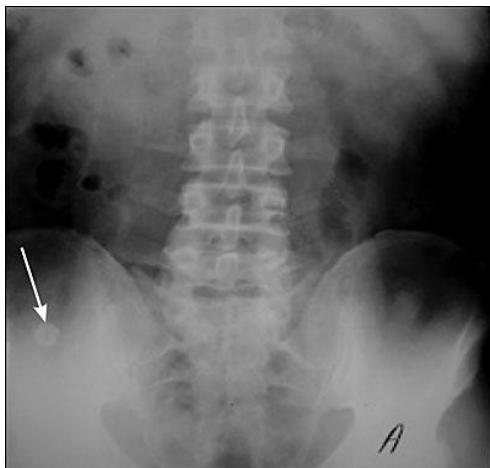

**Figure 3:** Acute suppurative appendicitis in a 15-year-old boy; contrast-enhanced, fat-suppressed, T1-weighted, spin-echo coronal magnetic resonance image

## 2.7 X ray

Actually, plain abdominal radiography (PAR) is not useful in the diagnosis of appendicitis and should not be routinely test in a person being evaluated for appendicitis. (51, 52). Plain abdominal films may be useful for the detection of ureteral calculi, small bowel obstruction, or perforated ulcer, but these conditions are rarely confused with appendicitis. A barium enema has proven to be a poor diagnostic tool for appendicitis (Figure 4). While failure of the appendix to fill during a barium enema technique has been associated with

appendicitis, about 20% of normal appendices also do not fill (52, 54).



**Figure 4:** Plain radiographic image of the abdomen revealing an appendicolith (arrow) in the right lower quadrant

## 2.8 Management

In case of acute appendicitis is typically managed by surgery, while in uncomplicated cases antibiotics are both more effective and safe. Sometime antibiotics are effective for treating uncomplicated appendicitis but 20% of patients had a recurrence within a year and required eventual appendectomy (52, 55).

## 2.9 Pathology

The decisive option of appendicitis diagnosis is based on pathology. The histologic findings of appendicitis is neutrophilic infiltrate of the muscularis propria. Periappendicitis, while tissues inflammation around the appendix, is often found in conjunction with other abdominal pathology (56).

## 2.10 Pain

Usually during appendicitis the pain medications (such as morphine) do not appear to affect the accuracy of the clinical diagnosis of appendicitis and therefore should be given early in the person's care. Historically there were concerns among some general surgeons that analgesics would affect the clinical exam in children and thus some recommended that they not be given until the surgeon in question was able to examine the person for themselves (57).

## 2.11 Surgery

surgical procedure for the removal of appendix is called an appendectomy. Laparoscopic technique (via three small incisions with a camera to visualize the area of interest in the abdomen) seem to have some advantages

instead of open procedures especially in young females and the obese (58).

## 2.12 Laparotomy

Traditional type of treating for appendicitis is surgery. This procedure included the removal of infected appendix through a single larger incision at the lower right area of the abdomen. Length of that incision is usually 2 to 3 inches (51 to 76 mm). This kind of surgery is used also for visualizing and examining to the structures inside of abdominal cavity and it is named exploratory laparotomy. During a traditional appendectomy procedure, the patient with suspected appendicitis is placed under general anesthesia to keep the muscles completely relaxed and to keep the person unconscious. This incision which is equal two to three inches long and it is made at right lower abdomen, several inches must be above the hip bone. Once the incision opens all abdomen cavity organs included the appendix it will be appeared, the surgeon should removes the infected tissue and cuts the appendix from the surrounding tissue. After careful and close inspection of the infected area, and ensuring there are no signs that surrounding tissues are infected or damaged, the surgeon will start closing the incision; that means sewing of muscles and using surgical staples or stitches to close the skin up to prevent any infections as well as incision must be covered with a sterile bandage (48,51).

## 2.13 Laparoscopic

The modern technique to treat appendicitis is the laparoscopic surgery. This procedure consists of making three to four incisions in the abdomen, each 0.25 to 0.5 inches (6.4 to 12.7 mm) long. During this technique of appendectomy surgeon will insert a special surgical tool called laparoscope into one of that three incisions. The laparoscope is connected with outer monitor and it is designed to help the surgeon to inspect the infected area in the abdomen. The other two incisions are made for the specific removal of the appendix by using surgical instruments. Laparoscopic surgery also requires general anesthesia and it can last up to two hours. In India where there is no incision on the external skin and SILS (single incision laparoscopic surgery) where a single 2.5 cm incision is made to perform the surgery (58).

## 2.14 Pre surgery

Treatment procedure begins by keeping the patient who will be having surgery from eating or drinking for a given period of time, usually overnight. An intravenous solution is used to hydrate the person who will be having surgery. Several antibiotics such as cefuroxime and metronidazole usually given intravenously to help kill bacteria as well as to reduce the spread of infection in the abdomen and postoperative complications in the abdomen or wound.

Equivocal cases may be difficult to evaluate with antibiotic treatment and benefit from serial examinations. In case stomach is empty (no food in the past six hours) general anaesthesia is usually used. Otherwise, spinal anaesthesia may be used (59).

Usually, the risks of appendicitis are different from one case to another depending on the state of the appendix. If the appendix has not ruptured, the complication rate risks are only about 3% while if the appendix has ruptured, the complication risk rate rises to almost 59%. The most usual complications that can occur during appendectomy are pneumonia, hernia of the incision, thrombophlebitis, adhesions or bleeding. Recent studies indicates that a delay in obtaining surgery after admission results in no measurable difference in outcomes to the person with appendectomy (59,60). One of the important things that must be taken into account by surgeon how long the recovery process should take. The hair at abdomen is usually removed in order to avoid any complications that may appear regarding the incision. In most of the appendicitis, persons going in for surgery experience vomiting or nausea which requires specific medication before surgery. Some antibiotics along with pain medication may also be administered prior to appendectomies (60,61).

### 2.15 After Surgery

The typically stay at hospital ranged from a few hours to a few days, but can be several days if the complications occur. The recovery process depending on the severity of the condition, if the appendix had ruptured or not before appendectomy. Appendectomy surgery recovery process is generally a lot faster if the appendix did not rupture. Any patients undergoing surgery must be respected to their doctor's advice and limit their physical activity so the tissues can heal faster. Recovery process after an appendectomy surgery may not require diet changes or a lifestyle change (52).

After surgical operation, the patient will be transferred to care unit so his or her vital signs can be closely monitored to detect anesthesia and observe any surgery-related complications. Anti-Pain medications may also be administered if necessary. When patients are completely awake, they are sent into a hospital room to recover. The diet of most patients will be clear liquids during the day after the surgery, then progress to a regular diet when the intestines start to function properly. all appendectomy patients must be recommended to sit up on the edge of the bed and walk short distances for several times a day. Slow traffic is mandatory and pain medication may be given if necessary. Full recovery from appendectomies takes about four to 42-45 days, but can be prolonged to up to 56-60 days if the appendix had ruptured (27).

### 3. Appendicitis and Genetic background

The correlation between genetics and appendicitis are not well understood and so a heritability analysis and

genome wide linkage analysis of a large twin dataset was undertaken. The correlation between the inheritance and appendicitis refers to whether the causes is inherited from our parents or "runs" in families. The level of inheritance of a condition depends on how important genetics factors are to the disease. Usually strongly genetic diseases are inherited, whereas partially genetic diseases are sometimes inherited, and non-genetic diseases are not inherited absolutely (62).

In the light of previous studies, we can suggest that half of the variability in risk of acute appendicitis is due to genetic factors. A positive family history increases the relative risk factors of being acute appendicitis nearly 3 times. In 2000 and 2007 several studies reported that there is strongly correlation between appendicitis and IL-6 gene polymorphism (63,64).

Polymorphism in the IL-6 gene was associated with the severity of appendicitis, even after adjustment for duration of symptoms. The risk for developing appendiceal perforation or gangrene may be determined, in part, by variation in the IL-6 gene (65).

### References

- [1]. Benjamin IS, Patel AG. Managing acute appendicitis, (2002), *BMJ*, 325:505–506
- [2]. Buckius MT, McGrath B, Monk J, Grim R, Bell T, Ahuja, (2012), Changing epidemiology of acute appendicitis in the United States: study period 1993-2008, *J Surg Res.* 15;175(2):185-90.
- [3]. Ellis, H, (March 2012), "Acute appendicitis.". *British journal of hospital medicine*, V. 73 (3): C46–8.
- [4]. Kai-Biao Lin, Chien-Lung Chan, Nan-Ping Yang, Robert K Lai, Yuan-Hung Liu, Shun-Zhi Zhu, Ren-Hao Pan,(2015), Epidemiology of appendicitis and appendectomy for the low-income population in Taiwan, 2003–2011, *BMC Gastroenterology*, 15:1 .
- [5]. Guinnessworldrecords.com. (2011), Guinness world record for longest appendix removed, PP. 10-03.
- [6]. Golalipour, M.J.; Arya, B.; Jahanshahi, M.; Azarhoosh, R, (2003), "Anatomical Variations Of Vermiform Appendix In South-East Caspian Sea (Gorgan-IRAN), *J. Anat. Soc. India* V. 16, PP 45-5.
- [7]. Gedda L, Sciacca A, Brenci G et al, (1984), Situs viscerum specularis in monozygotic twins, *Acta Genet Med Gemellol* , 33 (1): 81–5.
- [8]. O Ngim, L Adams, A Achaka, O Busari, O Rahaman, I Ukpabio, D Eduwem, (2013), Left-Sided Acute Appendicitis With Situs Inversus Totalis In A Nigerian Male – A Case Report And Review Of Literature, *The Internet Journal of Surgery*, V.30 (4),PP.55-60.
- [9]. Kumar, Vinay; Robbins, Stanley L.; Cotran, Ramzi S, (1989), Robbins' pathologic basis of disease (4th ed.), *Philadelphia: Saunders*, pp. 902–3.
- [10]. Everett M.L., Palestrant D., Miller S.E., Bollinger R.R., Parker W, (2004), Immune exclusion and immune inclusion: a new model of host-bacterial interactions in the gut, *Clinical and Applied Immunology Reviews* 5 (5): 321–32.
- [11]. Paterson-Brown, S, (2007), 15. The acute abdomen and intestinal obstruction". In Parks, Rowan W.; Garden, O. James; Carter, David John; Bradbury, Andrew W.; Forsythe, John L. R. Principles and practice of surgery (5th ed.), *Edinburgh: Churchill Livingstone*, 443-10157-4.

- [12]. Bollinger, R.R.; Barbas, A.S.; Bush, E.L.; Lin, S.S.; Parker, W, (2007), Biofilms in the large bowel suggest an apparent function of the human vermiform appendix, *Journal of theoretical biology* 249(4): 826-831.
- [13]. Sonnenburg J.L., Angenent L.T., Gordon J.I, (2004), Getting a grip on things: how do communities of bacterial symbionts become established in our intestine?", *Nat. Immunol.* 5 (6): 569-73.
- [14]. Dehghan A, Moaddab AH, Mozafarpour S (June 2011). "An unusual localization of trichobezoar in the appendix". *The Turkish Journal of Gastroenterology* 22 (3): 357-8. مكرر
- [15]. MBD (July 22, 2013) "Scientists Finally Discover the Function of the Human Appendix." [1]
- [16]. Smith H. F., Parker W., Kotzé, S. H., Laurin, M, (2013), Multiple independent appearances of the cecal appendix in mammalian evolution and an investigation of related ecological and anatomical factors". *Comptes rendus Palevol.*
- [17]. Sci.waikato.ac.nz. Animal Structure & Function". Retrieved, (2011), PP. 10-03.
- [18]. Smith H. F., Fisher R. E., Everett M. L., Thomas A. D., Bollinger, R. R., Parker W, (2009), Comparative anatomy and phylogenetic distribution of the mammalian cecal appendix. *Journal of Evolutionary Biology*, 22 (10): 1984-1999.
- [19]. Darwin, Charles, (1871), *The Descent of man, and Selection in Relation to Sex.*
- [20]. Appendix disorders Symptoms, Diagnosis, Treatments and Causes, (2010), Wrongdiagnosis.com. Retrieved PP. 05-19.
- [21]. Graffeo, CS; Counselman, FL, (1996), Appendicitis, *Emergency medicine clinics of North America*, V.14, No. (4), PP.653-71.
- [22]. Miller R., Kenneth; Levine, Joseph, (2002), *Biology*. Prentice Hall. pp. 92-98.
- [23]. Pieper R, Kager L, Tidefeldt U, (1982), Obstruction of appendix vermiformis causing acute appendicitis. One of the most common causes of this is an acute viral infection which causes lymphoid hyperplasia and therefore obstruction. An experimental study in the rabbit, *Acta Chir Scand*, V. 148, No. (1), pp. 63-72.
- [24]. Dan L. Longo, (2012), *Harrison's principles of internal medicine*. (18th ed.). New York: McGraw-Hill. p. Chapter 300.
- [25]. McGraw-Hill, Medical Pub. Division, (2010), p. Chapter 30. *Schwartz's principles of surgery* (9th ed.), New York.
- [26]. Tintinalli, editor-in-chief Judith E, (2011), *Emergency medicine : a comprehensive study guide* (7. ed. ). New York: McGraw-Hill. p. Chapter 84.
- [27]. Barrett, ML; Hines, AL; Andrews, RM, (2013), Trends in Rates of Perforated Appendix, 2001-2010: Statistical Brief #159". *Healthcare Cost and Utilization Project (HCUP) Statistical Briefs.*
- [28]. Hollerman J. et al, (1988), Acute recurrent appendicitis with appendicolith, *Am J Emerg Med*, V.6, No. (6), pp. 614-7.
- [29]. Jones BA, Demetriades D, Segal I, and Burkitt DP, (1985), The prevalence of appendiceal fecaliths in patients with and without appendicitis. A comparative study from Canada and South Africa, *Ann. Surg.*, V. 202, No. (1), pp. 80-2.
- [30]. Nitecki S, Karmeli R, Sarr MG, (1990), Appendiceal calculi and fecaliths as indications for appendectomy, *Surg Gynecol Obstet*, V. 171, No. (3), pp. 185-8.
- [31]. Arnbjörnsson E, (1982), "Acute appendicitis as a sign of a colorectal carcinoma, *J Surg Oncol*, 20 (1): 17-20.
- [32]. Dehghan A, Moaddab AH, Mozafarpour S, (2011), An unusual localization of trichobezoar in the appendix". *The Turkish Journal of Gastroenterology*, 22 (3): 357-8.
- [33]. Raahave D, Christensen E, Moeller H, Kirkeby LT, Loud FB, Knudsen LL, (2007), Origin of acute appendicitis: fecal retention in colonic reservoirs: a case control study, *Surg Infect (Larchmt)* 8 (1): 55-62.
- [34]. Burkitt DP, (1971), The aetiology of appendicitis, *Br J Surg*, 58 (9): 695-9.
- [35]. Segal I, Walker AR, (1982), Diverticular disease in urban Africans in South Africa, *Digestion* 24 (1): 42-6.
- [36]. Arnbjörnsson E, (1982), "Acute appendicitis as a sign of a colorectal carcinoma, *J Surg Oncol*, 20 (1): 17-20.
- [37]. Adamis D, Roma-Giannikou E, Karamolegou K, (2000), Fiber intake and childhood appendicitis, *Int J Food Sci Nutr*, 51 (3): 153-7
- [38]. Hugh TB, Hugh TJ, (2001), Appendectomy--becoming a rare event, *Med. J. Aust*, 175 (1): 7-8.
- [39]. Ashdown, H. F.; D'Souza, N.; Karim, D.; Stevens, R. J.; Huang, A.; Harnden, A, (2012), Pain over speed bumps in diagnosis of acute appendicitis: diagnostic accuracy study, *BMJ*, 345 (14): e8012-e8012.
- [40]. Sachdeva, Anupam, and Dutta, AK, (2012), *Advances in Pediatrics, JP Medical Ltd.* p. 1432.
- [41]. Huang, Ih-Ping; Smith, C Daniel, (2006), Cope's Early Diagnosis of the Acute Abdomen, 21st Edition, *Annals of Surgery*, 244 (2): 322.
- [42]. Rovsing, N. T, (1907), Indirektes Hervorrufen des typischen Schmerzes an McBurney's Punkt. Ein Beitrag zur diagnostik der Appendicitis und Typhlitis". *Zentralblatt für Chirurgie, Leipzig*, 34: 1257-1259.
- [43]. Small V, (2008), *Surgical emergencies*. In Dolan B and Holt L (eds) *Accident and Emergency: Theory into Practice*, 2nd edition. Elsevier.
- [44]. Paulson EK, Kalady MF, Pappas TN, (2003), Suspected Appendicitis, *N Engl J Med*, 348:236-242
- [45]. Beltran MA, Almonacid J, Vicencio A, Gutierrez J, Cruces KS, and Cumsille MA, (2007), Predictive Value of White Blood Cell Count and C Reactive Protein in Children with Appendicitis, *J of Ped Surg*, 42:1208-1214.
- [46]. Krishnamoorthi, R.; Ramarajan, N.; Wang, N. E.; Newman, B.; Rubesova, E.; Mueller, C. M.; Barth, R. A, (2011), Effectiveness of a Staged US and CT Protocol for the Diagnosis of Pediatric Appendicitis: Reducing Radiation Exposure in the Age of ALARA, *Radiology*, 259 (1): 231-239
- [47]. Wan, M. J.; Krahn, M.; Ungar, W. J.; Caku, E.; Sung, L.; Medina, L. S.; Doria, A. S. , (2009), "Acute Appendicitis in Young Children: Cost-effectiveness of US versus CT in Diagnosis--A Markov Decision Analytic Model, *Radiology*, 250 (2): 378-386.
- [48]. Terasawa T, Blackmore CC, Bent S, Kohlwes RJ, (2004), Systematic review: computed tomography and ultrasonography to detect acute appendicitis in adults and adolescents, *Annals of Internal Medicine*, 141 (7): 537-46.
- [49]. Aydin F, Kin Cengiz A, Güngör F, (2012), Tc-99m Labeled HMPAO white Blood Cell Scintigraphy in Pediatric Patients, *Mol Imaging Radionucl Ther*, 21(1):13-8.
- [50]. Herliczek TW, Swenson DW, Mayo-Smith WW, (2013), Utility of MRI after inconclusive ultrasound in pediatric patients with suspected appendicitis: retrospective review of 60 consecutive patients. *AJR Am J Roentgenol*. 200(5):969-73
- [51]. Rao PM, Rhea JT, Rao JA, Conn AK, (1999), "Plain abdominal radiography in clinically suspected appendicitis: diagnostic yield, resource use, and comparison with CT", *The American Journal of Emergency Medicine*, 17 (4): 325-8.

- [52]. Boleslawski E, Panis Y, Benoist S, Denet C, Mariani P, Valleur P, (1999), Plain abdominal radiography as a routine procedure for acute abdominal pain of the right lower quadrant: prospective evaluation, *World Journal of Surgery*, 23 (3): 262–4.
- [53]. Sabiston *Textbook of Surgery*, 2007.
- [54]. Kulik, DM; Uleryk, EM; Maguire, JL, ( 2013), Does this child have appendicitis? A systematic review of clinical prediction rules for children with acute abdominal pain, *Journal of clinical epidemiology*, 66 (1): 95–104.
- [55]. Varadhan KK, Neal KR, Lobo DN, (2012), Safety and efficacy of antibiotics compared with appendicectomy for treatment of uncomplicated acute appendicitis: meta-analysis of randomised controlled trials, *BMJ*, 344: e2156.
- [56]. Fink AS, Kosakowski CA, Hiatt JR, Cochran AJ, (1990), Periappendicitis is a significant clinical finding, *American Journal of Surgery*, 159 (6): 564–8.
- [57]. Anderson, M; Collins, E, (2008), "Analgesia for children with acute abdominal pain and diagnostic accuracy, *Archives of Disease in Childhood*, 93 (11): 995–7.
- [58]. Sauerland, S; Jaschinski, T; Neugebauer, EA, ( 2010), Laparoscopic versus open surgery for suspected appendicitis, *Cochrane Database of Systematic Reviews* (10):552-8.
- [59]. Siewert B1, Raptopoulos V, Liu SI, Hodin RA, Davis RB, Rosen MP, (2003), *Radiology*, CT predictors of failed laparoscopic appendectomy, Nov;229(2):415-20.
- [60]. CBC News, (2010), pp. 9-21.
- [61]. Eypasch, E., S. Sauerl and, R. Lefering, and E. A. Neugebauer, ( 2010), Laparoscopic versus Open Appendectomy: Between Evidence and Common Sense, *Digestive Surgery*, 19 (2010): 518–522.
- [62]. Oldmedow, C, Mengersen, K, Martin, N & Duffy, DL, ( 2009), Heritability and Linkage Analysis of Apendicitis Utilizing Age at Onset', *Twin Research and Human Genetics*, v. 12, no. 2, pp150-157.
- [63]. Ergul E1,( 2007), Heredity and familial tendency of acute appendicitis, *Scand J Surg*. 96(4).
- [64]. Ivanhoe A. Gamboa-Ojeda, Alberto Vázquez-Benítez, Elías Lorenzana-Merlín, Dra. María Santa Leticia Sánchez-Cuautle, (2000), Probable genetic background in acute appendicitis, *Cir Ciruj*, 68: 148-153.
- [65]. Fernando A. Rivera-Chavez, MD, Dixie L. Peters-Hybki, MS, Robert C. Barber, PhD, Guy M. Lindberg, MD, Ishwarlal Jialal, MD, PhD, Robert S. Munford, MD, and Grant E. O'Keefe *Ann Surg*, ( 2004), Innate Immunity Genes Influence the Severity of Acute Appendicitis, 240(2): 269–277.