

The outcome of Laser Assisted Uvulopalatoplasty in management of snoring patients

Dr.Sajad Alhelo*.MD.CABS(ORL-HNS), Dr.Zeena Alshamma M.B.ch.B. and Hazim Mohammed Khudair* FICMS CABS

Chief of Arabic Board Najaf Center, Iraq
Najaf Center, Iraq
Medical City; Ghazi Al-Hariri Surgical Specialties Hospital, Iraq

Accepted 13 Jan 2017, Available online 17 Jan 2017, Vol.5 (Jan/Feb 2017 issue)

Abstract

Introduction: Snoring is very common in general population affecting around 35-40 % of men and 15-28% of women, it is caused by a partial upper airway collapse during sleep. The most common site of obstruction is the soft palate. There are a number of surgical procedures for the management of snoring .One of these surgical procedure is laser assisted uvulopalatoplasty (LAUP) which involves partial resection of the uvula and soft palate using a CO2 laser.

Aim of study: to evaluate the effect of single stage laser assisted uvulopalatoplasty in management of snoring caused by obstruction at the level of the soft palate.

Patients and Methods: A non controlled clinical trial(interventional prospective) was carried out in the operating room of otorhinolaryngology, head and neck surgery department in Al-Sader Medical city in An-Najaf city ,from April 2015 to January 2016.the study involves 50 patients with loud snoring. All the patients subjected to a detailed sleep questionnaire **Epworth sleepiness scale (ESS)**,all the patients had underwent müller maneuver (Mm), then Laser assisted uvulopalatoplasty was performed.

Results: 50 patients were enrolled in this study ,the percentage of males were(78%),while the percentage of females were (22%),with a mean age (45.8±9.6 years) .(82%) were improved whereas only (10%) were not improved and the rest (8%) shown partial improvement.

Conclusion: Laser assisted uvulopalatoplasty is safe and efficient method for snoring reduction .it is minimally invasive procedure with on need for special preparation before operation,being quick and easy to perform under local anesthesia ,it is very important for proper selection of patients before operation. in this study, LAUP diminished snoring in the majority of patients, it had a positive effect on snoring in 82% of cases.the major drawback is postoperative pain seen in 56% of cases which is mild.

Keywords: Laser, Laser Assisted Uvulopalatoplasty, Snoring

Introduction

Snoring is a sound generated by the vibration of the pharyngeal soft tissue, it is often louder during inspiration than expiration.¹Snoring is an important social problem seen in both men & women. it is caused by a partial upper airway collapse during sleep. The most common site of obstruction is the soft palate ,however other regions of upper airway tract may cause snoring like the nose , base of the tongue , tonsils and epiglottis.²Snoring can occur either as a primary snoring (simple or non – apneic snoring) which is caused by minimal airway obstruction as a part of syndrome (obstructive sleep apnea syndrome) which is caused by complete obstruction.³There are a number of surgical procedures for the management of non –apneic snoring and the most appropriate treatment options depend on the level

of airway obstruction .⁴ One of these surgical procedure is laser assisted uvulopalatoplasty (LAUP) which is a day care surgical procedure involves partial resection of the uvula and soft palate using a CO2 laser during one to several sessions , this procedure is first described by Kamami in 1990.^{5,6}

Patients and Method

A non controlled clinical trial (interventional prospective)study was carried out in the operating room at otorhinolaryngology ,head and neck surgery department in Al-Sader Medical city in An-Najaf city ,from April 2015 to January 2016.the study was performed on 50 patients of loud snoring, patients were advised to bring their bed partners in order to explain the severity of snoring during sleep, all the bed partners described the

*Corresponding author's ORCID ID: 0000-0000-0000-0000

DOI: <https://doi.org/10.14741/ijmcr/v.5.1.9>

snoring as a loud(4-6) on the basis of scale of subjective snoring (Stanford)⁷

Table 1: Scale of Subjective Snoring (Stanford)

Grade	Classification	Notes
0	No Snoring	
1 - 3	Mild	doze not disturb the partner during sleep
4 – 6	Loud	enough to disturb the partner
7 – 9	Very High	disturbs people in other room
10	Intense	the partner leave the room

All the patients answered a detailed sleep questionnaire **Epworth sleepiness scale (ESS)**⁴, the score was obtained using standardized questions in which patients rated, on scale of 0 to 24. ESS <11 regarded as normal, mild subjective day time sleepness (11-14), moderate day time subjective sleepness (15-18), severe day time sleepness (>18). The results were recorded pre and post (LAUP).

Epworth Sleepiness Scale

- 0 = Would never doze
- 1 = Slight chance of dozing
- 2 = Moderate chance of dozing
- 3 = High chance of dozing

Situation	Chance of dozing
1. Sitting and reading	_____
2. Watching TV	_____
3. Sitting, inactive in a public place (e.g., a theatre or a meeting)	_____
4. As a passenger in a car for an hour without a break	_____
5. Lying down to rest in the afternoon when circumstances permit	_____
6. Sitting and talking to someone	_____
7. Sitting quietly after a lunch without alcohol	_____
8. In a car, while stopped for a few minutes in traffic	_____
Total	_____

During the initial visit all patient underwent a routine otorhinolaryngology examinations, the sex , age , neck circumference (NC) (measured in centimeters) ,body mass index (BMI), were recorded. Müller maneuver (MM)⁸.was done to all patients , it was done by using a flexible nasopharyngoscopy & performed with the patient in sitting position after topical nasal anesthesia ,a flexible nasopharyngoscope was inserted through the anesthetized nasal cavity to the lower oropharynx. The collapse of the soft palate level (anteroposterior or lateromedial) and oropharynx (lateral pharyngeal wall &

the base of the tongue) was assessed during a maximal inspiratory effort against a closed mouth and sealed nose (reverse Valsalva) the nasopharyngoscope was withdrawn to a level which was just cephalad to passavants ridge. Collapse of the soft palate was again assessed during a maximal inspiratory effort against a closed mouth and sealed nose .the obstruction of the regions that collapsed with Müller maneuver, where the patients were awake and in a sitting position was evaluated:-

- No obstruction (0)
- up to (25%) obstruction (1)
- up to (50%) obstruction (2)
- up to (75%) obstruction(3)
- and (100%) obstruction(4)

The inclusion criteria1- patients with loud ,disruptive snoring 2-the obstruction was at the level of the uvula.
The exclusion criteria 1- hyperactive gag reflex,2- mandibular retrognathia ,3-mandibular micrognathia, 4- big tonsils 5-patients with velopharyngeal insufficiency6- hyperatrophy of the base of the tongue.

LAUP performed under local anesthesia which, in sitting position, topical anesthesia is used (10% xylocaine) which is sprayed in the posterior oral cavity. Then an injection of lidocaine 1% with 1:100,000 epinephrine. The patient wore a protective eye glasses, Surgical use of the carbon dioxide laser (fig 1) was commenced after waiting 10 minutes for the anesthesia to take its effect.



Figure 1 CO2 laser system that used in this study

A special pharyngeal hand piece with a backstop (fig2) was used to incise the soft palate.

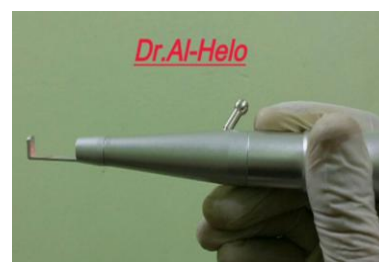

Figure 2 The pharyngeal hand piece with a backstop

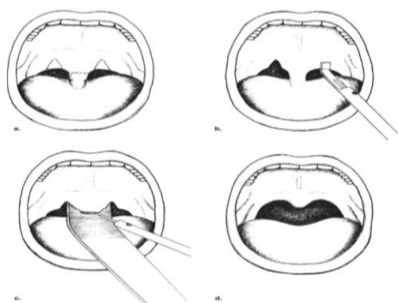
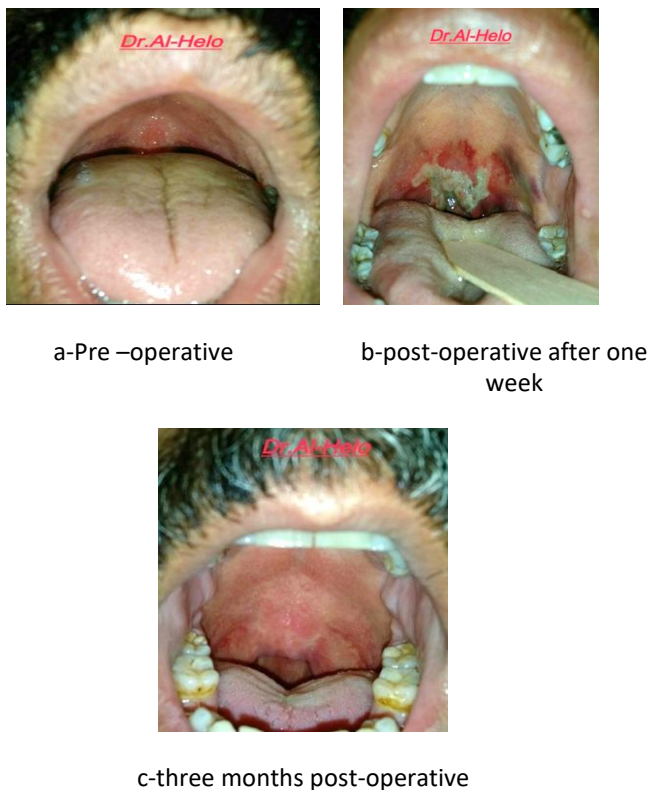

Figure 3 Diagrammatic representation of (LAUP)



a-Pre –operative

b-post-operative after one week

c-three months post-operative

Figure 4 LAUP

The power setting is 10 Watts, continuous mode. The tongue was retracted inferiorly with tongue blade with the integrated smoke-evacuation channel. Through-and-through, full-thickness, vertical trenches measuring 1.0 cm were made on the free edge of the soft palate on either side of the uvula.(fig3) Shortening and thinning of the uvula were performed with the carbon dioxide (CO₂):laser. The uvula is reduced (60% to 90%) of its original dimensions (5mm of the uvula was kept in order to ensure proper cleaning of the secretions of the posterior pharyngeal wall). No additional surgical procedures such as tonsillectomy, nasal surgery, glossectomy or mandibular surgery were performed in any of these. Light bleeding during surgery occurred and controlled easily by cold water.

The postoperative care included Analgesia, Antibiotic and mouth wash. All the patients re-examined after one week for any complications (fig 4b) and reexamined after 3 months (fig4c) by müller maneuver to assess the

outcome, all the patients underwent ESS again after 3months & their partner came with them to explain the grade of snoring according to stanford scale.

Result

The study included50 patients complaining from snoring, their age was(28-60),with mean±SD is 45.8±9.6 years, the percentage of male distrubution is higher than female as shown in figure(5).

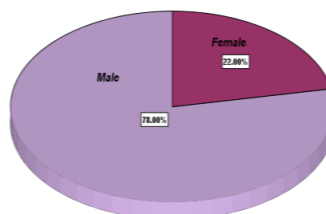


Figure 5 Gender distribution of the studied group

Table 2 Outcome of patients after 3 months of operation

	Frequency	Percent
No snoring	41	82
Mild snoring	4	8
loud snoring	5	10
Total	50	100.0

Table 3 Comparison between patients according to outcome

variable	Outcome			P value
	No snoring (n=41) Mean±SD	Mild Snoring (n=4) Mean±SD	Loud snoring (n=5) Mean±SD	
Age/years	45.78±9.39	49.25±11.58	43.8±11.88	0.705
BMI Kg/m ²	31.11±3.19	32.05±4.29	31.49±6.06	0.869
Neck circumference/cm	43.07±3.19	42.75±3.94	40.8±4.86	0.381
Duration of operation/min	13±3.44	12±4	12.6±2.5	0.84

The outcome of patients after 3 months of operation indicate that the higher percentage in no snoring group followed by loud snoring & finally mild snoring group as shown in table(2).

There are no significant differences in age, BMI, neck circumference, duration of operation among all groups as shown in table (3).

Table 4 Epworth Sleepness Scale (EPSS) and müller maneuver pre and post operation

	Mean	Std. Deviation	P value
EPSS preop	15.1200	1.79159	<0.001
EPSS postop	11.0400	1.87312	
Muller maneuver preop	3.2600	0.750	<0.001
Muller maneuver postop	1.54	0.788	

The EPSS & Müller maneuver were significantly lower 3 months postoperatively than that before operation as shown in table(4).

Table 5 Distribution of patients according to Complications during operation

	Frequency	Percent
mild bleeding	4	8.0
no	46	92.0
Total	50	100.0

The results indicate that the frequency of patients without bleeding is higher than those with mild bleeding s shown in table (5).

Table 6 Frequency and percentage of complications after one week after operation

	Frequency	Percent
no complication	8	16.0
pain	28	56.0
pain & infection	12	24
pain, mild bleeding, infection	2	4.0
Total	50	100.0

These result indicate that the higher percentage of complications is feeling of pain 56% followed by 24% those with pain& infection, while only 4% with no complications as shown in table (6).

Discussion

Outcome of patients after 3 months of operation

Concerning the outcome of loud snoring patients after 3 months were 82% have no snoring (i.e improved) whereas only 10% remain loud sonring (i e not improved) and the rest were 8% showing mild snoring(partial improvement) this subjective result depend on the patient and the partner explication according to stanford scale (Thuler ER *et.al.* 2002)⁷, the reason why there is improvement of snoring is most likely due to removal of the obstruction at the level of the uvula and soft palate, while those who show no any improvement (remain loud snoring) may be there is another cause of snoring beside palatal obstruction, like smoking. And those with mild snoring (partial improvement),the reason may be due to unreliable description of the snoring by the partner, these result nearly comparable with other study (Kamami YV 1990)⁵ who studied 517 patients found that 70% of them improved,25% have partial improvement and only 5% have no improvement. Other investigator (walker RP etal 1996)⁹ reported that in 105 patients,60% improvement,29% partial improvement &10% no improvement. While (Utley DS *et.al.* 1997)¹⁰ show 72.7% of patients improved, (Klozer J *et.al.* 2007)² show 88% improved & 12no improvement but this study used a visual analogue scale for assessment of snoring. while (Verma R 2007)¹¹ show out of all 195 patients ,156 patients(80%) had excellent response, 23 moderate response & 16 patient poor response, while (Abdullah B *et.al.* .2008)⁷out of 19 patients 13 patients(68.4%) show improvement and the rest of the patients did not turn up for follow up after the operation (Olszewska E *et.al.* 2012)¹²show 80% improved and 20 % not improved).the result of this study disagree with (Ferguson K A. *et.al.*

2002)¹³ which show improvement only (52%) & no improvement (48%) the reason for this may be due to (Ferguson KA *et.al.* 2002)¹³ followed up the patient for longer period (7.2 months) and this may lowering the successful rate.

Comparison between patients according to outcome

There are no significant differences among the patients outcome (no snoring, mild snoring and loud snoring) in relation to the age, BMI, neck circumference and duration of operation as shown in table (3). This result agrees with (Larrosa F *et.al.* 2004)⁶ and (Ryan CR and Love LL 2000)¹⁴.

Epworth Sleepness Scale (EPSS) and müller maneuver pre and post operation.

The Epworth sleepness scale (EPSS) and muller maneuver were significantly lower after 3 months of operation than that before operation as shown in table (4). This is mainly because removal of the obstruction at the level of soft palate lead to improvement of snoring so the patients may have quit sleep at night so the Epworth sleepness scale decline from 15.12 ± 1.7 to 11.04 ± 1.87 . This result agrees with (Thuler E R *et.al.* 2002)⁷, (Utley D S. *et.al.* 1997)¹⁰ who show muller maneuver significantly decreased from 2.5 ± 1.3 to 0.9 ± 1.3 p value (<0.001)

And EPSS significantly decreased from 13.5 ± 4.4 to 8 ± 2.5 p value (0.002) and agrees with (Ryan C F & Love L L 2015)¹⁴ who reported that EPSS significantly decreased from 13 (5-19) to 8 (4-14) p value (0.003). But this result disagrees with (Ferguson K A *et.al.* 2002)¹³ and (Larrosa F *et.al.* 2004)⁶ who show that EPSS decreased from 10.7 ± 3.7 to 9.3 ± 3.8 but it was not significant, the reason for no significant changes in their study may be related to small sample size (21 patients), another reason may be the patients in Kathleen study had another reason for snoring beside the soft palate obstruction like septal deviation.

Distribution of patients according to Complication during operation

Concerning complications during operation out of 50 patients underwent laser assisted uvulopalatoplasty only 4 patients have mild bleeding which is likely due to puncture of the blood vessels of the uvula during the surgical procedure as the CO₂ laser with a focus beam may cause undesired bleeding from the soft palate vessel as shown in table (5) this result agrees with (Larrosa F, *et.al.* 2007)⁶ in which only one patient out of 33 patients have mild bleeding & (Ferguson k A. *et.al.* 2002)¹³ 4 patient out of 52 experienced mild bleeding & 5 patients (24%) reported moderate to severe bleeding. While (Berger G, *et.al.* 2001)¹⁵ no bleeding occurs in 14 patients.

Frequency and percentage of complications after one week after operation

The result indicate that the higher percentage (56.0%) of complication after one week after operation is pain next

to that (24%) is pain and infection whereas only (16%) have no complication and only (4%) have pain, infection and mild bleeding, the reason for the higher percentage of pain may be due to the thermal effect of laser and the threshold pain differ in different patient beside that the mucosal surface of the wound which can vary according to the extent of resection, while the reason of pain and infection is that the patients may not follow the instruction of the doctor, that is to say they do not take the medication in regular time also some patient have chronic illness like diabetes mellitus which increase the percentage of infection, while those with mild bleeding that occur after one week post operation may be due to infection as shown in table (6). The percentage of pain in this study is slightly higher than that reported by (Ferguson k A. *et.al.* 2002)¹³ who found that 17 subject out of 52 complained of moderate to severe pain. Other investigator (Klozar J, *et.al.* 2007)² found that in 104 patients there was 23 % of patient have mild pain. The reason for the higher percentage of pain may be due to more mucosal surface resection area of the wound during surgical procedure. Whereas the percentage of pain in our study is less than that reported by (Wareing M M 1996)¹⁶ (Berger G, *et.al.* 2001)¹⁵ who show that 74% of patients complained of pain, and the reason why our result showing less percentage of pain is that probably because of the use of low energy laser during the procedure which lead to less pain post operatively. However there was only one author (Abdullah B *et.al.* 2008)¹⁷ reported no any complication the reason for that may be due to small number of patients in his study (19 patients) which is not enough to show complication.

Conclusion

- 1-Laser assisted uvulopalatoplasty is safe and efficient method for snoring reduction.
- 2-it is minimally invasive procedure with no need for special preparation before operation, it is quick and easy to perform under local anesthesia.
- 3-proper selection of patients before operation is very important.
- 4-the major drawback is postoperative pain seen in 56% of cases which is mild.
- 5-limited effectiveness regarding patients with nasal obstruction, big tonsils, enlarged adenoid & hypertrophy in the base of the tongue.

References

- [1]. Tamekia L. Wakefield, Derek J. Lam and Stacey L. Ishman. Chapter 18, Sleep apnea and sleep disorders. In Paul W. Flint *et.al.* (ed.) Cummings Otolaryngology Head & Neck Surgery 6th ed. 2015 :253-266.
- [2]. Klozar J, Plzak J, Zabrodsky M, Betka J. Effectiveness and Side Effects of One –Stage Laser-Assisted Uvuloplasty in Primary Rhonchopathy: ORL 2007,69:316 -321
- [3]. Rashid M, Ahmed Z, and Manzoor T. Modified Palatal Stiffening Procedure for Snoring: Journal of the college of Physicians and Surgeon Pakistan 2011, vol. 21 (6):330 – 333.

- [4]. Main C, Liu Z, Welch K, Jones SQ, Stein K. Surgical procedures and non-surgical devices for the management of non-apnoeic snoring: a systemic review of clinical effects and associated treatment costs. *Health Technol Assess* 2009; 13 (3).
- [5]. Kamami YV. Laser CO2 for snoring: preliminary results. *Acta Otorhinolaryngologica Belg* 1990; 44: 451-456.
- [6]. Larrosa F, Hernandez L, Morello A, Ballester E, Quinto L, Montserrat J.M. Laser-assisted uvulopalatoplasty for snoring: does it meet the expectations? *European Respiratory Journal* 2004;24 :66-70.
- [7]. Thuler ER, Dibbern RS, Fomin DS, Oliveira JAA. laser-assisted uvulopalatoplasty-comparative analysis of the clinical improvement and the indication criteria, *Brazilian Journal of Otorhinolaryngology*. 2002 ; 68(2): 190-193.
- [8]. Borowiecki BD, Sassan JF. Surgical treatment of sleep apnea. *Arch Otolaryngol* 1983;109:508-512.
- [9]. Walker RP, Gatti WM, Poirier N, Davis JS. Objective Assessment of Snoring Before and After Laser – Assisted Uvulopalatoplasty. *Laryngoscope* 1996;106;11
- [10]. Utley DS, Shin EJ, Clerk AA, Terris DJ. A cost-effective and Rational surgical approach to patients with snoring, upper airway resistance syndrome, or obstructive sleep apnea syndrome. *Laryngoscope* 1997;107:726–34.
- [11]. Verma R. Laser Assisted Uvulopalatopharyngoplasty, *Indian J. Otolaryngol. Head Neck Surg*. 2007;59:108-110.
- [12]. Olszewska E, Rutkowska J, Rogowski M. Selected surgical management in snoring and obstructive sleep apnea patients. *Med Sci Monit*, 2012;18(1):13-18.
- [13]. Ferguson K A, Heighway K, Ruby R R F. A Randomized Trial of Laser –Assisted Uvulopalatoplasty in Treatment of Mild Obstructive Sleep Apnea. *Am J Respir Crit Care Med*, 2003;vol 167.pp 15-19.
- [14]. Ryan CF, Love L L. Unpredictable results of laser assisted uvulopalatoplasty in the treatment of obstructive sleep apnea. *thorax*, 2000;55:399-404.
- [15]. Berger G, Finkelstein Y, Stein G, Ophir D. Laser-assisted uvulopalatoplasty for snoring: medium to long-term subjective and objective analysis. *Arch Otolaryngol Head Neck Surg* 2001;127:412–17.
- [16]. Wareing M, Mitchell D. Laser –assisted uvulopalatoplasty: An assessment of a technique. *J Laryngol Otol*. 1996;110:232-236.
- [17]. Abdullah B, Othman A. , Khairi M. D. Outcome of Laser – Assisted uvulopalatoplasty (LAUP) in the Management of Snoring in Hospital University Stains Malaysia (USM): *Malays J Med Sci*. 2008 ;15(2): 29-32.