

## Choanal polyp originating from the uncinete process: Uncinochoanal polyp case report

Dr.Sajad Alhelo<sup>#\*</sup> MD.CABS (ORL-HNS) and Dr.Ahmed.J.Shanoon.MBChB.\*

<sup>#</sup>Consultant ORL-HNS.Chief of Arabic Board-Najaf Center-Iraq,

<sup>\*</sup>Najaf center-Iraq

Accepted 16 Jan 2017, Available online 17 Jan 2017, Vol.5 (Jan/Feb 2017 issue)

### Abstract

Choanal polyps are benign, solitary unilateral soft tissue lesions of sinonasal tract of unclear etiology, usually originate from maxillary sinus mucosa but in some reported cases it can originate from unusual sites. In the present report, we describe an extremely rare case of choanal polyp arising from uncinete process (uncinochoanal) in 22 year female managed in our department. The aim of this report is to highlight an unusual form of choanal polyp

**Keywords:** Choanal Polyp, Uncinate Process, Uncinochoanal

### Introduction

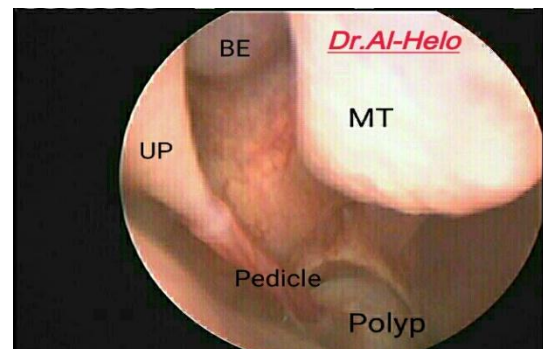
Choanal polyp (CP) was described by Professor Gustav Killian, in 1906. <sup>(1)</sup> Choanal polyps are unilateral sinonasal lesions that are classified according to their site of origin.<sup>(2)</sup> usually arise from the maxillary sinus and extend toward the nasopharynx.<sup>(3)</sup> In the review of literature ,Choanal polyps can originate from unusual locations such as the sphenoid sinus, ethmoid sinus, nasal septum, inferior turbinate , middle turbinate and soft or hard palate as a rare entity.<sup>(3) (4) (5)</sup> To our best knowledge ,no case of uncinochoanal polyp had been reported. Choanal polyps are mostly seen unilaterally, but rare cases of bilateral cases have been reported in the literature.<sup>(5)</sup>

The exact aetiology of choanal polyps is unknown.<sup>(6)</sup> It is more commonly seen in young age patients. When a young patient is presenting with complaints of unilateral nasal obstruction or hawking sensation we should have a high suspicion about Sino nasal polyposis. Diagnostic nasal endoscopy (DNE) and radiological study should be carried out followed by endoscopic sinus surgery forms the protocol of management for choanal polyps.<sup>(6)</sup>

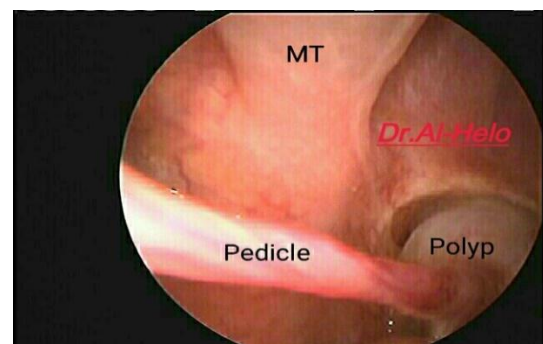
### Case report

A 22 year old female presented with right sided nasal obstruction for about 6 months duration. The condition had become progressively worse over time, no nasal discharge, no facial pain and no smell abnormalities. Medical history was unremarkable. Endoscopic nasal examination revealed right side grayish polypoidal mass based in the postero- inferior aspect of the uncinete process with a thin pedicle and the polyp was hanging

loosely through the choana. The remaining of the otorhinolaryngologic examination did not reveal any abnormalities.



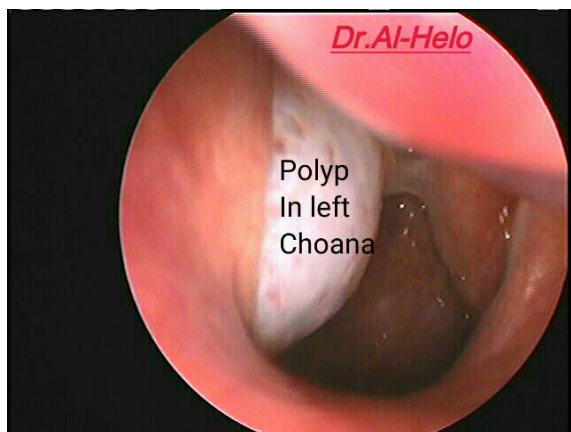
**Figure 1:** Endoscopic picture showing the choanal polyp attached by a pedicle to the uncinete process.( UP= uncinete process, MT= middle turbinate , BE= bulla ethmoidalis)



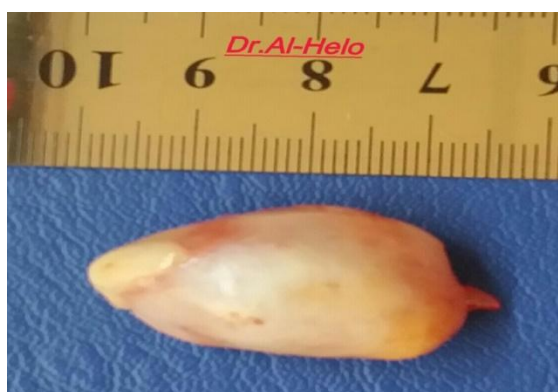**Figure 2:** The polyp filling the right choana

\*Corresponding author's ORCID ID: 0000-0000-0000-0000

DOI: <https://doi.org/10.14741/ijmcr/v.5.1.10>



**Figure 3:** Polyp seen from left choana



**Figure 4:** Polyp had been removed

Endoscopic polypectomy was performed under local anesthesia, Polyp was grasped by forceps and pulled posteriorly moved into the nasopharynx and removed transorally. Histological examination revealed chronic inflammatory polyp. There was no recurrence during a follow-up period of 18 months.

### Discussion

Choanal polyps are solitary benign unilateral sinonasal polyps of unknown etiology.

Polypoid nasal mucosa and polyp formation is a poorly understood condition that may be a multifactorial (Allergy, chronic inflammation, turbulent air flow and gravity).<sup>(7)</sup>

Although there are different types of choanal polyps, most of them arise from maxillary sinus and are called "antrochoanal polyps". Choanal polyp can originate from the ethmoid sinus, sphenoid sinus, inferior or middle nasal concha, nasal septum in rare cases.<sup>(3)</sup>

A choanal polyp arising from the uncinete process is extremely rare and not reported in literature, In our case, CP is originating from posteroinferior portion of uncinete process. Although varying in location, CPs present with same symptoms and histological findings as in our case, the most common symptom is nasal obstruction.<sup>(3)(4)</sup>

The differential diagnosis of CP should include angiofibroma, haemangioma, lymphoma, retention cyst, mucocele, mucopyocele, inverted papilloma, turbinate hypertrophy, adenoid hypertrophy, Tornwaldt's cyst and olfactory neuroblastoma. In particular, inverted papilloma should be considered if there is an unusual site of origin of a CP.<sup>(8)</sup>

Endoscopic sinus surgery is recommended treatment and provides low recurrence rate 3.

### Conclusion

Choanal polyps can arise from unusual locations and should be kept in mind in the diagnosis and management of unilateral nasal obstruction.

### References

- [1]. P Frosini, G Picarella, and E De Campor; Antrochoanal polyp: analysis of 200 cases; Acta Otorhinolaryngol Ital. 2009 Feb; 29(1): 21–26.
- [2]. Adhami M, Coste A, Escabasse V, Chalumeau F.; The inferior turbinate, an unusual site for a choanal polyp: Two case reports and a review of the literature; Ear Nose Throat J. 2016 Jul;95(7):E1-4
- [3]. Ethem İlhan , Mehmet Ali Özel , Fahri Halit Beşir, Hüseyin Yaman ; A case of choanal polyp originating from middle turbinate , Entcase e-ISSN: 2149-7877
- [4]. Murat YARIKTAFI, M.D., Harun DO/RU, M.D., Fehmi DONER, M.D.,
- [5]. Mustafa TUZ, M.D., Hasan YASAN, M.D.; Choanal polyp originated from the inferior turbinate presenting as nasal polyposis. Kulak Burun Bogaz İhtis Derg 2006;16(1):37-40
- [6]. Huseyin Yaman, MD Suleyman Yilmaz, MD Elif Karali, MD Ender Guclu, MD Ozcan Ozturk, MD ; Evaluation and Management of Antrochoanal Polyps ; Clinical and Experimental Otorhinolaryngology Vol. 3, No. 2: 110-114, June 2010
- [7]. Ajay Manickam , Shaswati Sengupta , Debangshu Ghosh , Sebananda Haldar, Jayanta saha , SK Basu & Souradeep Ray; Choanal Polyps of Unusual Presentation – A Series of 4 Cases ; Global Journal of Medical Research: J Dentistry and Otolaryngology Volume 15 Issue 2 Version 1.0 Year 2015
- [8]. Hakan Birkent, Serdar Karahatay, Abdullah Durmaz, Bülent Kurt, Fuat Tosun, Choanal polyp originating from the nasal septum: septochoanal polyp Kulak Burun Bogaz İhtis Derg 2009;19(3):163-166
- [9]. Özkırış M. Choanal Polyp Originating From The Middle Turbinate: A Case Report ACU Sağlık Bil Derg. 2012;3:187-189