

Modified Stoppa's Procedure-The Call Over to the Surgeons

Dr.C.Selvaganesh M.S. and Dr.P.Rajapandi M.S*

Dept. of General Surgery, government Villupuram medical college, Tamilnadu, India

Received 06 March 2018, Accepted 08 May 2018, Available online 11 May 2018, Vol.6 (May/June 2018 issue)

Abstract

Background: Inguinal hernia – the foreword for all surgeons in their professional career, has always been a mystery box for each and every new case. Even with its oldest history in treatment, it is still the emerging area in the field of surgery.

Aim: To evaluate and analyze the prognosis of the modified STOPPA'S ^{1,2} procedure in the management of bilateral inguinal hernia

Methodology: This work was carried out between AUGUST-2011 to AUGUST-2013, in the period of two years, totally 30 patients were included in the study including direct, indirect and combined. The results were studied on basis of length of hospitalization, major and minor complication, recurrence rates.

Results: The outcome at the end of 1 year of follow-up was excellent. None of the patient developed recurrence, whereas other complications were less than 10% individually. Follow up was done for 5 years completely.

Conclusion: stoppa procedure has an established place in the treatment of bilateral inguinal hernias and also recurrent hernias, with the modification that has been carried out in this study, the nowadays forgotten and less preferred procedure will gain its power due to its effectiveness.

Keywords: Inguinal hernia, STOPPA'S etc

Introduction

"HERNIA" is the base of a surgeon and also surgery, has its own innovations which has led to many new procedures and modification in the basis of prognosis in already existing ones. From bassini's to linchtenstein's³ or from shouldice to dhasaradha's^{4,5} the anatomical repairs has been evolved to the meshplasty which reduced the recurrence and also other complications. When mesh were used the plane of surgery become a question mark? Which still exists leading to the preferences of different procedures among the surgeons, of which stoppas was a milestone.

It involves placing a large prosthetic material in the preperitoneal space deep to transversalis fascia to cover the myopectineal orifices on both sides, which acts as a new abdominal layer rather than a fascia preventing not only inguinal hernias but also any other type of hernia occurring through the myopectineal orifice by withholding the raised intra-abdominal pressure. Other factor was, since it was a posterior preperitoneal repair, so called the virgin plane with no nerves and minimal cord handling. These factors added its credit to the preference of the procedure over Lichtenstein repair mainly for

reducing recurrence. Yet it is to be accepted that on the emergence of laparoscopic plasty, the procedure has lost its popularity In this study, some more modifications has been implemented which makes and will make it a worth competitor for other repairs.

Methodology

The study was carried under the department of general surgery, government villupuram medical college, villupuram, tamilnadu, India. All patients with bilateral inguinal hernia were taken into the study between time period of AUGUST 2011 to AUGUST 2013. Patients including direct, indirect and combined ones were included here. Patients with complication of hernia such as a strangulated or obstructed hernia, with a midline scar, with previous laparotomy and patients with blood disorders were excluded here. Follow up was done for 5 years.

Procedure

With the informed consent of the surgery, Preoperative anaesthetic fitness and bladder catheterization was done. All patients under the study was operated under spinal anaesthesia. Lower midline vertical incision was made below the umbilicus, skin and fascial layers dissected,

*Corresponding author's ORCID ID: 0000-0002-2719-2845

DOI: <https://doi.org/10.14741/ijmcr/v.6.3.5>

anterior rectus sheath is opened with midline incision and preperitoneal space was identified and extended using blunt and sharp dissection. Retropubic space also explored. Both sides were looked for indirect and direct sacs. Cord structures were identified and separated from hernial sac. For INDIRECT hernias the sac was opened and suture closed. For DIRECT hernias the sac was pushed back. A prolene mesh of size about 30cms×30cms tailor made chevron shaped and kept in the space. Mesh is fixed inferiorly to coopers ligament on both sides, superolaterally fixed in the anterior abdominal wall. Wound closed in layers. 16F suction drain kept on both sides. The continuous bladder drainage (CBD) were removed on the first postoperative day. All patients were discharged on the fifth postoperative day. Patients were monitored for complications in both early and late postoperative period. Evaluation of the patient was made on day 7, day 15, 1 month, 3 months, 6 months, 12 months, 18 months and 24 months after surgery for complication like recurrence and chronic groin pain.

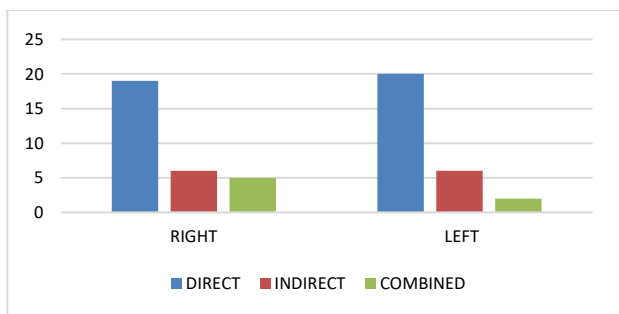
Modification in the Stoppas

1. Chevron shaped tailor made prolene mesh was used
2. Fixation of the mesh is done both inferiorly to cooper’s ligament and superolaterally to the anterior abdominal layer.

Results

30 patients in the study are totally males, out of which the types of hernia are shown in the table

	Direct	Indirect	Combined
Right	19	6	5
Left	20	6	4



All patients underwent the MODIFIED STOPPAS PROCEDURE under SPINAL ANAESTHESIA. Catheter was removed on first day and all patients were discharged on fifth day after surgery.

The results of the study after the follow-up evaluation was quite interesting, because none had recurrence in four years of follow-up period. None even had complication like urinary retention, deep or superficial wound infection. Complications have occurred in less than 8% of the patients which includes seroma and spinal headache. There was no mortality.

Complications	No.of patients	Percentage
Early		
Seroma	2	6
Spinal headache	2	6
Urinary retention	0	0
Wound infection	0	0
Early recurrence	0	0
Late		
Late recurrence	0	0
Chronic groin pain	0	0
MORTALITY	0	0

Conclusion

SINGLE INCISION, SINGLE MESH BILATERAL REPAIR WITHOUT RECURRENCE, what else would a surgeon and a patient would need out of a repair... with the above said modification adding to the simplicity, excellent results and outcomes, the procedure becomes an wise agenda in the treatment of bilateral hernias. Hopefully, still the procedure seems to be awaited to gain its control over the laparoscopic methods.

References

- [1]. Stoppa RE. Giant prosthesis for replacement of visceral sac in the repair of groin and incisional hernia. In Fisher JE, Bland KI. Master’s of Surgery. 5th edition, Lippincott Williams and Wilkin’s. 2007;1924-30.
- [2]. . Stopp RE. The preperitoneal approach and prosthetic repair of groin hernias. In: Nyhus LM, Condon RE. Hernia. 4th ed. Philadelphia. J. B.
- [3]. Lichtenstein IL, Shulman AG, Amid PK (1989) The tension-free hernioplasty. Am J Surg 157:188–193.
- [4]. Desarda MP. New method of inguinal hernia repair: a new solution. ANZ J Surg. 2001;71:241–244. doi: 10.1046/j.1440-1622.2001.02092.x.
- [5]. Desarda MP. Inguinal herniorrhaphy with an undetached strip of external oblique aponeurosis: a new approach used in 400 patients. Eur J Surg. 2001;167:443–448. doi: 10.1080/110241501750243798